

Clinical and Confocal Microscopy Study of Plasma Exeresis for Nonsurgical Blepharoplasty of the Upper Eyelid: A Pilot Study

ELENA ROSSI, MD,* FRANCESCA FARNETANI, MD,* MYRTO TRAKATELLI, PHD,^{†‡} SILVANA CIARDO,* AND GIOVANNI PELLACANI, PHD*

BACKGROUND Plasma exeresis is an evolving technique for nonsurgical treatment of several skin conditions. Reflectance confocal microscopy (RCM) is a noninvasive tool that allows the “in vivo” imaging of the skin.

OBJECTIVE To evaluate the clinical improvement and collagen remodeling of the upper eyelid dermatochalasis after plasma exeresis.

METHODS Ten patients were subjected to 3 interventions of plasma exeresis. Photographic and RCM images were acquired at T0 (baseline) and T1 (4–6 weeks after final plasma exeresis). Eyelid dermatochalasis was rated as absent, mild, moderate, and severe according to the facial laxity rating scale, at clinical images at T0 and T1. An expert RCM evaluator classified collagen according to the predominant pattern of reticulated, coarse, huddled, or curled at T0 and T1.

RESULTS Clinical improvement of 2.6 ratings was observed at clinical evaluation. Collagen was classified as long straight fibers in all cases, according to RCM images.

CONCLUSION Plasma exeresis in this pilot study shows promising remodeling effects on the collagen of the upper eyelid, as viewed by RCM, and clinically improved appearance for the patient cohort, without any serious adverse events. This study suggests that plasma exeresis could be a valid solution for eyelid dermatochalasis, but further studies are required.

The authors have indicated no significant interest with commercial supporters.

One of the first areas to show signs of aging is the periorbital region.^{1,2} This area is considered by patients as one of the principal aspects of facial aesthetic appearance and is often selected for facial rejuvenation.^{3,4} There are several possible medical and surgical treatments available, such as laser therapy and blepharoplasty,^{5–7} and plasma exeresis is currently emerging as a minimally invasive therapeutic alternative.

Laser therapy uses photon emission (with spatial and temporal coherence) to destroy, vaporize, and coagulate tissue, whereas electrosurgical/radio scalpel therapy uses radio waves to increase tissue heat. Plasma exeresis ionizes gases present in the spatial gap between the

proximal tip of the instrument and the tissue being treated. Plasma is generated through the tip of the device in the form of an ultra gas-like state of matter, and the energy created is transferred onto the superficial skin layer. The tissue is sublimed; a direct transfer of the tissue from a solid form to a gaseous state is created. Direct contact with the skin is avoided. Because an electric passage zone is not created, eventual electric resistance of the tissue does not influence tissue sublimation. The heat is absorbed by the tissue being treated and is not transferred to surrounding tissue or the subcutis.

The safety of plasma exeresis in an animal model has been demonstrated by Scarano and colleagues⁸;

*Department of Dermatology, University of Modena and Reggio Emilia, Modena, Italy; †Department of Dermatology, Aristotle University, Papageorgiou Hospital, Thessaloniki, Greece; ‡Department of Dermatology, St. Pierre Hospital, Brussels, Belgium

© 2017 by the American Society for Dermatologic Surgery, Inc. Published by Wolters Kluwer Health, Inc. All rights reserved.
ISSN: 1076-0512 • Dermatol Surg 2017;0:1–8 • DOI: 10.1097/DSS.0000000000001267

plasma was shown to limit the damage within the connective parenchyma, enabling faster healing, both in the immediate and postoperative reparative processes as compared with electrosurgical/radio scalpel therapy. Plasma exeresis has been used in human aesthetic medicine for perioral wrinkles⁹ eyelid dermatochalasis¹⁰ and other benign skin conditions.¹¹ Most recently, 2 case reports have been published,^{12,13} investigating plasma exeresis on human skin biopsies at histology, confirming Type III collagen fibers and remodeling following plasma exeresis.

Histology requires invasive measures, and the results are obtained from a vertical section, with only partial visualization. The study area is limited to the area excised. Collagen bundles, however, are not anatomically oriented to the conventional relaxed skin tension lines. Further, excision is complex in the evaluation of aesthetic therapies, as scarring may be left. Alternatively, reflectance confocal microscopy (RCM) enables an “in vivo,” noninvasive identification of cells and tissues of the dermal matrix,^{14–20} producing an optical biopsy. Single, high-resolution images acquired from the top of the skin surface, up to 200 μm (stack), enables a layer-by-layer exploration of the entire epidermis and upper dermis. Recently, RCM has been successfully applied on a large scale to assess skin changes through the aging process, identifying different collagen patterns correlated to histopathology.²¹ Longo and colleagues²² delineated the skin changes with RCM, occurring after laser skin rejuvenation, at the epidermal and dermal levels, highlighting collagen with long straight fibers and the onset of neocollagenesis.

The current study aims to evaluate the clinical improvement and “in vivo” collagen remodeling of eyelid dermatochalasis after plasma exeresis on the upper eyelid, as documented by clinical and RCM images.

Materials and Methods

Patients

Patients' inclusion criteria included photo skin Type I–III, and the presence of moderate to severe laxity of the

eyefold according to the facial laxity rating scale.²³ Exclusion criteria included active infection, tendency to form hypertrophic scars, previous medical treatment of the area (botulinum toxin, fillers, chemical peels, lasers, and intense pulse light), or oral retinoid drug prescribed within the past 6 months. All patients provided informed written consent.

Treatment

After gentle cleaning of the tissue to treat, a topical anesthetic cream (Emla; Astrazeneca, Luton, United Kingdom) with occlusive medication was applied and left to rest for 30 minutes. The area was then revealed and disinfected with benzalchonium (Citrosil; Manetti & Roberts, Firenze, Italy).

All cases were treated with the Plexr device (GMV, Rocca Priora, RM, Italy) in a private practice office by the same operator (E.R.). The Plexr is a cordless microsurgical hand operated device and was chosen principally because the energy is transferred to the fluid in the superficial skin layer,¹³ without transmitting any heat to the eye. The device was set to the single spot mode, and treatment was administered

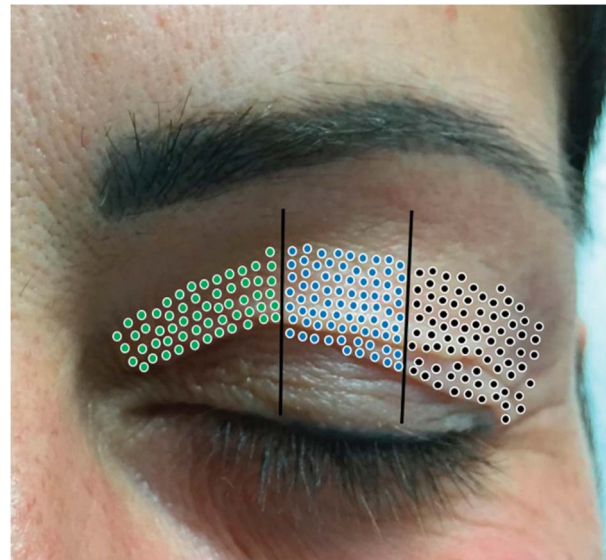


Figure 1. Examples of the treatment areas (the spots) performed in a triangular format; the treatment is never performed on the bottom of the wrinkles or furrows. The areas treated in the 3 sessions are indicated by different colored spots: the lateral area (black spots) at the first visit, the central area (blue spots) at the second visit, and the medial area (green spots) at the third visit.

according to a single-pass treatment (for no longer than 2 seconds at each spot), and the spots were spaced closely together. Overlapping of the spots was avoided. Plasma exeresis was performed on excess tissue and treatment was divided into 3 sessions, 30 days apart. At each session, treatment was limited to an area of 30% of the upper eyelid surface. The lateral side of each eyelid was treated in the first session, the central part in the second, and the medial side in the final session (Figure 1).

A hypoallergenic fluid foundation (Toleriane Teint, La Roche Posay, France) was applied immediately after the procedure to protect the area and to cover the visual signs (small scabs) of treatment. Patients were given written instructions for post-treatment care. Including indications to wash the treatment area with neutral soaps only, disinfect the area twice a day, apply hypoallergenic fluid foundation daily until scabs spontaneously fell off, and to avoid manual removal of the scabs and sun exposure for at least 1 month.

Images

Clinical images were collected with VISIA (Canfield, Fairfield, NJ) in frontal projections with the eyes open and then closed at T0 (1–7 days before the first treatment) and T1 (4–6 weeks after the last plasma exeresis sitting). Reflectance confocal microscopy images were performed on the central area of the eyelid and obtained with a near-infrared reflectance confocal laser scanning microscope (Vivascope3000; MAVIG GmbH, Munich, Germany) that scans the skin horizontally from the epidermis to the papillary dermis (diode laser, 830-nm laser beam with a maximum power of 35 mW) at T0 and again at T1. At each recording, 2 stacks were taken to obtain a complete horizontal section of the area.

Parameters/Measurements

Clinical images were evaluated for upper eyelid skin dermatochalasis improvement using the facial laxity rating scale according to nine degrees: absent (0), mild (1–3), moderate (4–6), and severe (7–9).²³ Images were

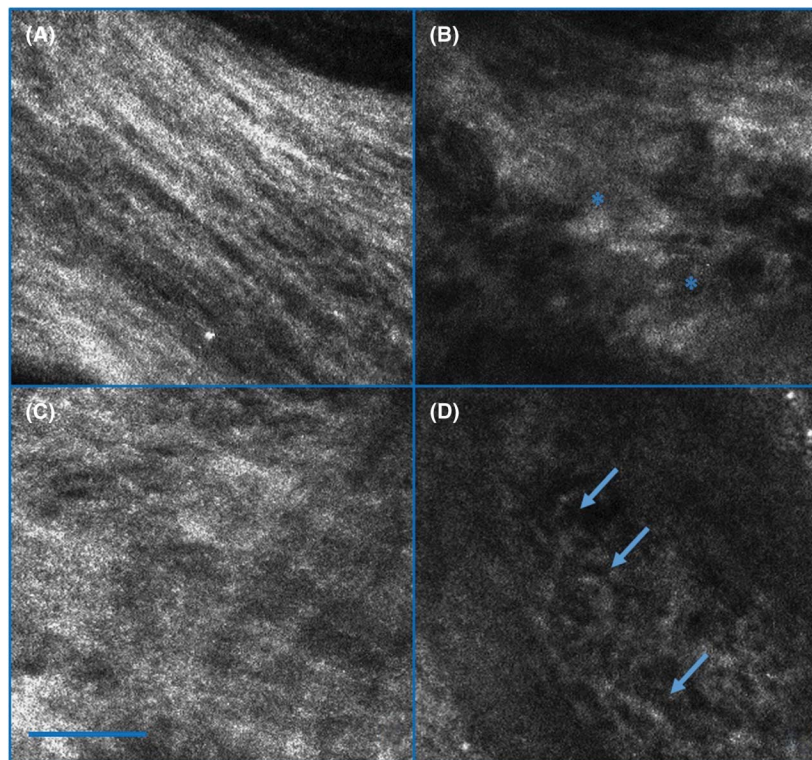


Figure 2. Dermal matrix architecture at reflectance confocal microscopy (RCM): reticulated collagen (A), huddled collagen (B) with the large hyporefractive blotches of amorphous and hyporefractive material in evidence (asterisks). Coarse collagen (C) and curled collagen (D) with the highly refractive thick and wavy fibers, which sometimes form compact masses in evidence (arrows). Scale bar = 50 μm .

evaluated by a blinded dermatologist (not involved in treatment or in image acquisition), from projections in different sessions on a screen, with the images appearing in random order.

Reflectance confocal microscopy images were reviewed by an expert in RCM imaging, blinded to clinical and demographic data, and classified according to the aspects of collagen viewed at the superficial dermal level, ranging between 80 and 120 μm. The 4 different patterns reported in the skin aging process²¹ were used for the initial classification of the predominant collagen pattern at T0 and T1.²² Reticulated collagen (Figure 2A) is usually present in young, healthy skin without sun damage. It is constituted by bright, thin fibrillary structures creating a web-like pattern. Huddled collagen (Figure 2B) is characterized by different degrees of collagen degeneration and corresponds to large hyporefractive blotches of amorphous and hyporefractive material. Coarse collagen (Figure 2C) is represented by different degrees of collagen degeneration and corresponds to coarse filamentous structures with a tendency to be packed. A web-like pattern is still observed but with larger and irregularly space meshes. Curled collagen (Figure 2D) structures are represented by fragmented fibers within a severe solar elastosis and correspond to highly refractive thick and wavy fibers, sometimes forming compact masses and individual collagen fibers are no longer visible and bright.

The patient follow-up included a final visit with the dermatologist at 30 to 45 days (T1) after the third plasma exeresis session. Time to scab healing, erythema, end edema were reported in person by the patient and recorded by the dermatologist.

Results

During a period of 8 months, 10 patients were enrolled with moderate and severe upper eyelid dermatochalasis. Patient demographic, preoperative, and post-operative clinical and RCM evaluations are listed in Table 1. All patients were women and caucasian, aged between 40 and 72 years old, with skin photo Types I–III. All subjects completed the scheduled visits and image recordings (no drop out).

TABLE 1. Patient Demographic and Upper Eyelid Characteristics for All Female Patients Included in the Study, With Clinical and RCM Improvement

Patient No.	Age, yrs	Skin Phototype	Eyelid Dermatochalasis		Predominant Collagen Pattern, T0	Eyelid Dermatochalasis, T1	Predominant Collagen Pattern, T1	Time to Scab Healing		Time to Erythema Healing, d	Edema, d	Hyperpigmentation
			T0	T1				d	d			
1	69	II	8	6	Huddled	6	Long straight fibers	5	28	2	No	
2	55	II	7	4	Coarse	4	Long straight fibers	7	40	2	No	
3	52	I	6	3	Huddled	3	Long straight fibers	6	30	3	No	
4	58	III	7	5	Huddled	5	Long straight fibers	4	35	2	No	
5	72	II	8	7	Huddled	7	Long straight fibers	3	28	3	No	
6	56	III	6	3	Huddled	3	Long straight fibers	6	36	2	No	
7	40	I	7	4	Coarse	4	Long straight fibers	7	36	3	No	
8	65	II	8	5	Coarse	5	Long straight fibers	3	30	2	No	
9	48	II	6	3	Huddled	3	Long straight fibers	5	28	2	No	
10	59	II	6	3	Coarse	3	Long straight fibers	6	30	2	No	

RCM, Reflectance Confocal Microscopy.

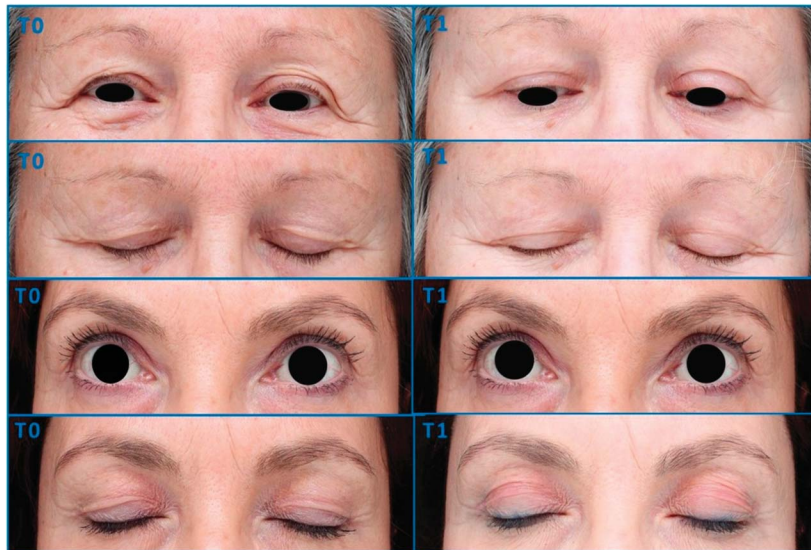

Figure 3. Examples of clinical improvement after 3 sessions of plasma exeresis. Note the restoration of the asymmetry.

At T0 according to the clinical scale for upper eyelid dermatochalasis, 4 patients were classified as moderate, and 6 as severe. Clinically at T1, all patients showed improvement of the upper eyelid rating after nonsurgical blepharoplasty (Figure 3). Improvement in terms of grades was observed in all patients; 7 improved by 3 grades, 2 improved by 2 grades, and 1 by a single grade, resulting in an overall average clinical improvement of 2.6 grades.

No major side effects were recorded at any time. A short-lasting, moderate edema immediately after treatment was recorded in all patients (Figure 4). Scab healing was achieved within 3 to 7 days. The erythema of the treated area lasted between 25 and 40 days. No hyperpigmentation occurred in any subject.

At baseline (T0), the predominant collagen pattern observed at RCM was classified as huddled in 6 patients and coarse in 4 patients. At T1, the

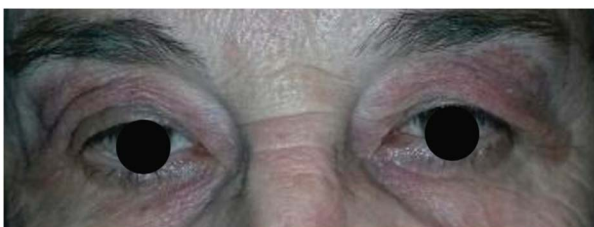

Figure 4. Edema the day after the treatment. Scabs are minimized by the application of fluid foundation.

predominant collagen pattern was noted in all 10 patients as long, straight fibers (Figure 5).

Discussion

The eyelid with a “rested” and youthful appearance is central to successful facial rejuvenation.¹⁻⁴ There are many techniques available for the treatment of eyelid dermatochalasis, including both invasive and non-invasive treatments. Technique selection is based on patient surgical risk, patient preferences, and operator experience. Plasma exeresis is a promising minimally invasive technique but data in literature regarding its effectiveness are limited.

Surgical blepharoplasty is still today a commonly requested procedure for eyelid dermatochalasis and has been associated with excellent results in expert centers.²⁴ However, its application is limited due to some contraindications associated with patient comorbidities. Surgical blepharoplasty has been associated with several but very rare complications, such as ectropion, hollow appearing eyelid sulcus (from over correction), vision loss (from retrobulbar hematomas 0.005% or globe perforation), and diplopia (from impaired ocularmotility).²⁵⁻²⁷ Additional complications include corneal abrasion, lagophthalmos (3%), cellulitis (2%), postblepharoplasty ptosis (3%), dry eye syndrome, lower lid malposition, chemosis, asymmetry (7%), and scarring (5%).²⁷⁻²⁹

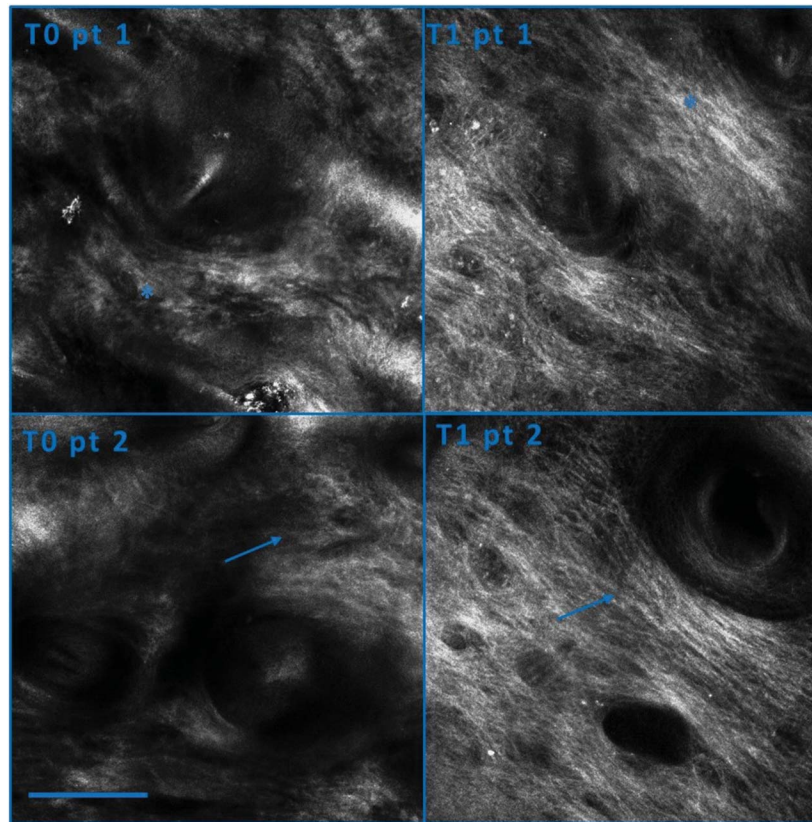


Figure 5. Dermal matrix architecture by reflectance confocal microscopy (RCM) of Patients 1 and 2: at baseline (T0), signs of skin aging characterized by a collagen with variable degrees of degeneration: in Patient 1 (T0 pt1) it was classified as huddled (asterisk) and in Patient 2 (T0 pt2) as coarse (arrow). At T1, a strong collagen remodeling process was detected in both patients: bright and long fibers with a parallel alignment are detected in Patient 1 (T1 pt1) and in Patient 2 (T1 pt2). Scale bar = 50 μ m.

Nonsurgical treatment of the upper and lower eyelid skin is often preferred by patients due to the non-invasive nature of the treatment, and can also be offered to patients at surgical risk. Results from laser treatment report reduced incidences of complications associated with surgery.³⁰ However, eye protection for both the patient and the operator is necessary to avoid injury from direct or indirect exposure to the laser beam³¹ but the eye shields are inserted directly on the eyeball between the upper and lower eyelids, and can be uncomfortable for the patient. Many other nonsurgical treatment options have been investigated in the search for satisfactory outcomes with less side effects and risks.^{5,7,32}

Plasma exeresis seems to be a promising, fast and safe, noninvasive solution due to its mechanism of action: the energy transferred from the device to the air gap, ionizes gases generating the plasma that is transferred to the

superficial skin layer. Compared with a monopolar radio scalpel unit, the main advantage is that no electric current is passed through the body of the patient, enabling the inclusion of patients with pace makers and cardiac stimulators. Compared with laser, the device acts on a more superficial area and, therefore, no specific target on the skin is needed and as it avoids the basal membrane, plasma exeresis seems less likely to provoke eventual vision or eye damage. The procedure can be executed with the application of a simple topical cream and does not need eye shields because there are no potential risks of the patients' vision (the heat created is absorbed by the tissue to treat only and is not transferred to surrounding tissue or the subcutis). The key advantages of this device are, therefore, the limited contraindications, reduced intraoperative pain, quick treatment and fast recovery, with a good cost-effectiveness ratio.⁹⁻¹³ Its application for nonsurgical blepharoplasty, therefore, seems advantageous.

The current patient selection included phototype I–III only. The current authors do not have any experience with darker skin phototypes and suggest that hyperpigmentation could be an issue. However, unpublished data suggest that plasma exeresis may be effective also in phototypes IV–VI, but further studies are required to confirm these findings.

The current study aimed to assess the clinical improvement and collagen remodeling of eyelid dermatochalasis after plasma exeresis for nonsurgical blepharoplasty according to clinical and RCM images. Histology was not performed so as to avoid scarring associated with biopsy, especially important in aesthetic procedures. Therefore, RCM was chosen as the preferred technique of skin morphology evaluation, given its noninvasive nature. If a biopsy was possible without causing scars, it would be the preferable methodology because more information is available from histology compared with RCM.

Plasma exeresis efficacy on the remodeling of tissue has been previously proven in humans through clinical evaluations and biopsy results in case reports of treatment on the upper limb only.^{12,13} In the current series, both clinical and RCM images at T0 were representative of collagen degeneration, responsible for the eyelid dermatochalasis. This current series seems to be the first study evaluating collagen remodeling at RCM after plasma exeresis in a patient series, albeit a small one. Reflectance confocal microscopy data suggest that the positive clinical results obtained by plasma exeresis nonsurgical blepharoplasty are related to the collagen reorganization and remodeling into new thick and bright collagen fibers with parallel alignment. The authors hypothesize that the thickened and parallel oriented collagen is able to generate tension on the skin, thus reducing the dermatochalasis, without any tissue loss. Similar changes have been observed after ablative fractional CO₂ laser sessions.²²

In this series, the only patient to have improved clinical appearance by 1 scale only was the oldest patient in the series. This raises the possibility that the mechanism of collagen remodeling may be dependent on patient age. Further, although plasma exeresis is not an alternative to surgery, it can be offered to patients with

contraindications for other techniques, or to improve results of previous traditional eyelid surgery.

The current study is limited by the homogeneous skin phototypes and sex represented in a small cohort. Further, only patients with moderate and severe eyelid dermatochalasis were included. The follow-up is limited and therefore further studies investigating plasma exeresis on a larger patient cohort, with more heterogeneous phototypes, with long-term follow-up will offer valuable information for durability and patient selection. Furthermore, RCM images do not give information about the dermal matrix composition, and ex vivo or in vivo investigations with the use of multiphoton microscopy³³ could eventually help to identify eventual chemical and/or biomolecular changes.

Conclusion

In this pilot study, plasma exeresis shows promising remodeling effects on the collagen of the upper eyelid and seems to improve appearance, without any serious adverse events. The current study suggests that plasma exeresis could be a valid solution for eyelid dermatochalasis, but further studies are required.

Acknowledgments The authors would like to thank Johanna Chester for her critical revision and editorial assistance.

References

1. Bucay VW, Day D. Adjunctive skin care of the brow and periorbital region. *Clin Plast Surg* 2013;40:225–36.
2. Mendelson BC, Hartley W, Scott M, McNab A, et al. Age-related changes of the orbit and mid cheek and the implications for facial rejuvenation. *Aesthetic Plast Surg* 2007;31:419–23.
3. Nguyen HT, Isaacowitz DM, Rubin PA. Age- and fatigue-related markers of human faces: an eye-tracking study. *Ophthalmology* 2009; 116:355–60.
4. Kwart DG, Foulsham T, Kingstone A. Age and beauty are in the eye of the beholder. *Perception* 2012;41:925–38.
5. Sundaram H, Kiripolsky M. Nonsurgical rejuvenation of the upper eyelid and brow. *Clin Plast Surg* 2013;40:55–76.
6. Codner MA, Wolfl JN, Anzarut A. Primary transcutaneous lower blepharoplasty with routine lateral canthal support: a comprehensive 10-year review. *Plast Reconstr Surg* 2008;121:241–50.
7. Fathi R, Pfeiffer ML, Tsoukas M. Minimally invasive eyelid care dermatology: medical, laser, cosmetic therapies. *Clin Dermatol* 2015; 33:207–16.

8. Scarano A, Carinci F, Sinjari B, Artese L, et al. Skin lesions induced from the radiosurgical unit and voltaic arc dermoabrasion: a rabbit model. *Eur J Inflamm* 2011;9:89–94.
9. Scarano A, Mortellaro C, Mavriqi L, Di Cerbo A. Evaluation effectiveness of the voltaic arc dermoabrasion in perioral rhytides eradication. *J Craniofac Surg* 2016;27:1205–8.
10. Tsioumas GS, Georgiadou I, Ntountas I. Upper blepharoplasty in relation to surgical blepharoplasty. *Pinnacle Med Med Sci* 2014;1:436–40. Article ID pmms_163.
11. Rossi E, Farnetani F, Pellacani G. Applicazioni della plasma exeresi in dermatologia. *Hi-Tech Dermo* 2016;2:17–22.
12. Tsioumas GS, Vlachodimitropoulos D, Goutas N. Clinical and histological presentation after plerx application, needle shaping (vibrance) and O.F.F. *Pinnacle Med Med Sci* 2014;2:522–30. Article ID pmms_178.
13. Gloustianou G, Sifaki M, Tsioumas GS, Vlachodimitropoulos D, et al. Presentation of old and new histological results after plasma exercises (plerx) application (regeneration of the skin tissue with collagen III). *Pinnacle Med Med Sci* 2016;983–90. Article ID pmms_241.
14. Rajadhyaksha M, Grossman M, Esterowitz D, Webb RH, et al. In vivo confocal scanning laser microscopy of human skin: melanin provides strong contrast. *J Invest Dermatol* 1995;104:946–52.
15. Rajadhyaksha M, Gonzalez S, Zavislan JM, Anderson RR, et al. In vivo confocal laser microscopy of human skin II: advances in instrumentation and comparison with histology. *J Invest Dermatol* 1999;113:293–303.
16. Gonzalez S, Sackstein R, Anderson RR, Rajadhyaksha M. Real-time evidence of in vivo leukocyte trafficking in human skin by reflectance confocal microscopy. *J Invest Dermatol* 2001;117:384–6.
17. Gill M, Longo C, Farnetani F, Cesinaro AM, et al. Non-invasive in vivo dermatopathology: identification of reflectance confocal microscopic correlates to specific histological features seen in melanocytic neoplasms. *J Eur Acad Dermatol Venereol* 2014;28:1069–78.
18. Reggiani C, Manfredini M, Mandel VD, Farnetani F, et al. Update on non-invasive imaging techniques in early diagnosis of non-melanoma skin cancer. *G Ital Dermatol Venereol* 2015;150:393–405.
19. Pellacani G, Scope A, Farnetani F, Casaretta G, et al. Towards an in vivo morphologic classification of melanocytic nevi. *J Eur Acad Dermatol Venereol* 2014;28:864–72.
20. Longo C, Farnetani F, Moscarella E, De Pace B, et al. Can noninvasive imaging tools potentially predict the risk of ulceration in invasive melanomas showing blue and black colors? *Melanoma Res* 2013;23:125–31.
21. Longo C, Casari A, Beretti F, Cesinaro AM, et al. Skin aging: in vivo microscopic assessment of epidermal and dermal changes by means of confocal microscopy. *J Am Acad Dermatol* 2013;68:e73–82.
22. Longo C, Galimberti M, De Pace B, Pellacani G, et al. Laser skin rejuvenation: epidermal changes and collagen remodeling evaluated by in vivo confocal microscopy. *Lasers Med Sci* 2013;28:769–76.
23. Leal Silva HG. Laxity rating scale validation study. *Dermatol Surg* 2016;42:1370–9.
24. Drolet BC, Sullivan PK. Evidence-based medicine: blepharoplasty. *Plast Reconstr Surg* 2014;133:1195–205.
25. Lelli GJ Jr, Lisman RD. Blepharoplasty complications. *Plast Reconstr Surg* 2010;125:1007–17.
26. Baker SS, Hunnewell M, Muenzler WS, Hunter GJ. Laser blepharoplasty: diamond scalpel compared to the free beam CO2 laser. *Dermatol Surg* 2002;28:127–31.
27. Golan S, Goldberg RA. Time course analysis of upper blepharoplasty complications. *Dermatol Surg* 2017;43:307–9.
28. Klapper SR, Patrinely JR. Management of cosmetic eyelid surgery complications. *Semin Plast Surg* 2007;21:80–93.
29. Morrow DM, Morrow LB. CO2 laser blepharoplasty. A comparison with cold-steel surgery. *J Dermatol Surg Oncol* 1992;18:307–13.
30. Rokhsar CK, Ciocon DH, Detweiler S, Fitzpatrick RE. The short pulse carbon dioxide laser versus the Colorado needle tip with electrocautery for upper and lower eyelid blepharoplasty. *Lasers Surg Med* 2008;40:159–64.
31. Kang DH, Koo Ries WR, Clymer MA, Reinisch L. Laser safety features of eye shields. *Lasers Surg Med* 1996;18:309–15.
32. Yates B, Que SKT, D'Souza L, Suchecki J, et al. Laser treatment of periocular skin conditions. *Clin Dermatol* 2015;33:197–206.
33. Benati E, Bellini V, Borsari S, Dunsby C, et al. Quantitative evaluation of healthy epidermis by means of multiphoton microscopy and fluorescence lifetime imaging microscopy. *Skin Res Technol* 2011;17:295–303.

Address correspondence and reprint requests to: Elena Rossi, MD, Department of Dermatology, University of Modena and Reggio Emilia, Modena 41121, Italy, or e-mail: dr.elenarossi@gmail.com